

CAROTID ARTERY STENT AND MEDICAL MANAGEMENT OF CAROTID DISEASE

Wei Zhou, MD, FICA

Division of Vascular and Endovascular Surgery, Stanford University, Stanford, California, U.S.A.

Keywords: stroke, TIA, carotid stenosis, carotid stent, carotid disease, medical management, carotid intervention, atherosclerosis

Contents

1. Carotid Disease
 2. Carotid Artery Stenting
 3. Medical Management
 4. Guideline Approaches
- Glossary
Bibliography
Biographical Sketch

Summary

Carotid Artery Stenting (CAS) has evolved as a valid alternative for patients with severe carotid artery stenosis, particularly those who are at high risk for surgery. Intense medical therapy has also shown significant benefits for stroke reduction in recent years. With improved medical management and excellent outcome of carotid endarterectomy, the indication for CAS is under fierce debate. Several societies have published guidelines on treatment strategies for carotid stenosis. Deciphering these guideline recommendations can be confusing. It is clear that symptomatic patients with a >50% carotid stenosis should be aggressively treated with surgical intervention and CAS reserved for high-risk patients. The consensus on asymptomatic patients is still lacking largely due to the data on the role medical therapy, which is limited. With currently improved medical therapy, it is reasonable to consider operative intervention in symptomatic patients with a >60% carotid stenosis and asymptomatic patients with a >80% stenosis if a 3-year life expectancy is reasonable. CAS should be reserved for high-risk patients. Asymptomatic patients who are offered carotid endarterectomy (CEA) should be informed their absolute risk reduction of stroke is only about 1% per year, and there is a small but non-negligible risk of perioperative stroke. Patients offered CAS should be informed that the risk profile remains higher than CEA, particularly in older patients. It is possible that with future advancements in technology, better patient selection, and operator proficiency, the difference in CAS and CEA will be less.

1. Carotid Disease

Stroke is one of the most common causes of permanent disability in industrialized countries, and is becoming increasingly prevalent around the world, and continues to be the third leading cause of death in the United States. Management of stroke consumes \$45 billion annually, and is responsible for greater than one million hospital admissions

each year in the U.S. (Thom et al., 2006). Neurologic sequelae related to stroke, such as paraplegia/paralysis, aphasia/dysphasia, and blindness, severely limit a patient's ability to carry out activities of daily living, which invariably create an enormous burden on our health care system. Extra-cranial carotid occlusive disease is one of the most common causes of stroke. Consequently, prevention of stroke with safe treatment of carotid occlusive disease becomes an important health care goal.

Atherosclerotic plaque buildup in the lumen of carotid arteries can lead carotid luminal narrowing, plaque ulceration or rupture, and arterial occlusion. Debris from the carotid plaque embolized distally into the brain is frequently the etiology for ischemic stroke or Transient Ischemic Attack (TIA). Similar to stroke, TIAs cause focal neurologic symptoms, such as contralateral paresis, paralysis, and/or paresthesia. Additional symptoms include vision disturbance and/or speech difficulties. Unlike stroke, TIA is a transit episode of neurologic dysfunction caused by ischemia without acute tissue death (infarction), and the symptoms typically last a few minutes and resolve within 24 hours. Having a TIA is a significant risk factor for another TIA episode or eventually a stroke. Statistically, up to 30% of patients will suffer a stroke within 90 days of the initial TIA symptoms. However, only 15% of patients who are at risk of devastating stroke present with sentinel events such as TIAs or amaurosis fugax (unilateral blindness). Nearly 75% of previously asymptomatic patients present to clinical attention with an unheralded stroke in a carotid artery distribution. Several well-designed and well-executed trials have demonstrated the benefit and superiority of carotid artery interventions in the management of carotid artery stenosis in patients who are symptomatic (North American symptomatic carotid endarterectomy trial collaborators 1991; Goldstein et al., 1995). Similarly, clinical trials have also investigated the role of surgical intervention in patients with asymptomatic carotid artery stenosis (Goldstein LB, Hasselblad V, Matchar DB, McCrory DC, 1995; The European carotid surgery trialists collaborative group, 1995). However, with the reported annual stroke risk of 2-5% stroke in asymptomatic patients with moderate to severe carotid artery stenoses, and much less in patients with mild carotid stenosis, the management of asymptomatic carotid artery stenosis has in recent years become an area of great interest as well as debate (Abbott, 2009).

2. Carotid Artery Stenting

Carotid artery endarterectomy has proven to be an effective treatment strategy to decrease the incidence of stroke and death in both symptomatic and asymptomatic patients with high-grade carotid stenosis (North American symptomatic carotid endarterectomy trial collaborators, 1991; Executive committee for the asymptomatic carotid atherosclerosis study, 1995). However, significant cardiopulmonary morbidities, such as New York Class III or IV congestive heart failure (CHF), chronic obstruction pulmonary disease (COPD) with forced expiratory volume in 1 second (FEV1) <50%, unstable angina, and recent myocardial infarction (MI) can potentially increase peri-operative cardiopulmonary complications in a subset of patients who undergo CEA. Furthermore, difficult surgical anatomies, such as recurrent stenosis following CEA, prior neck radiation or dissection, and inaccessible lesions above C2 level can also increase procedure-related complications. Based on the recommended guideline by the American Heart Association and Society of Vascular Surgery, CEA should only be

performed if the combined rate of perioperative stroke and death rate is less than 3% in asymptomatic patients and 6% in symptomatic patients with high-grade extracranial carotid stenosis (Brott et al., 2011; Ricotta et al., 2011). Consequently, alternative treatment strategies, such as carotid stenting (CAS) and medical management of carotid disease, have kindled significant enthusiasm in the medical community for patients with carotid stenosis. With perceived less invasiveness and short convalescence, new and innovative endovascular techniques, i.e. CAS, is considered an alternative for the treatment of carotid artery disease. It is increasingly adapted as the treatment of choice for asymptomatic patients, despite continuous concern for procedure-related cerebral embolization. Restriction of payment from Center for Medicare & Medicaid Services (CMS) has tempered the surge of CAS, and encouraged intense research on patient selection and evaluations on the benefits of aggressive medical management in high risk asymptomatic patients.

Although the indication for various treatment strategies is still debatable, several societies have published guidelines on treating patients with carotid stenosis. The Society for Vascular Surgery (SVS) recommends CEA as the first-line treatment for most symptomatic patients with stenosis of 50% to 99%, and asymptomatic patients with stenosis of 60% to 99% Indication (Ricotta et al., 2011). The SVS also recommends that CAS should be reserved for symptomatic patients with stenosis of 50% to 99% at high risk for CEA for anatomic or medical reason, and CAS is not recommended for asymptomatic patients at this time. Asymptomatic patients at high risk for intervention or with <3 years life expectancy should be considered for medical management as the first-line therapy. Recently, a joint task force involving 14 societies including the American Heart Association, American Stroke Association, American Society of Neuroradiology, Society of Interventional Radiology, and Society of Vascular Surgery recently published a practice guide on treating patients with carotid atherosclerotic disease (Brott et al., 2011). The guideline recommends CEA for patients with symptomatic >70% carotid stenosis as documented by noninvasive imaging or more than 50% as documented by catheter angiography if the anticipated rate of perioperative stroke or mortality is less than 6%. Based on the guideline, it is also reasonable to perform CEA in asymptomatic patients who have more than 70% stenosis if the risk of perioperative stroke, MI, and death is low. The guideline also stated that it was reasonable to choose CEA over CAS in older patients, and to choose CAS over CEA in patients with unfavorable anatomy.

2.1. Pre-operative Evaluation of Carotid Artery Stenting

Carotid artery stenosis is typically first evaluated with noninvasive duplex ultrasound imaging. The pre-procedure ultrasound should be performed by an accredited vascular imaging lab and by a certified technician. Preferably, the same vascular lab that will perform post-procedure ultrasound evaluations should be chosen for the pre-procedure ultrasound. The ultrasound B-mode image provides the operator with a rough estimate of the carotid artery diameter, characteristics of the atherosclerotic plaque, and evaluates the level of plaque surface ulceration and calcification. Equally important, the ultrasound also provides arterial waveforms of blood flow in the Internal Carotid Artery (ICA) and Common Carotid Artery (CCA), which can be used to extrapolate arterial peak systolic velocities, and the extent of carotid stenosis. The combination of ICA to

CCA peak systolic velocity ratio, end diastolic velocity of ICA, and peak systolic velocity of ICA yields relatively reliable values for inferring the extent of ICA stenosis.

Once the intervention is decided, the patient should have a detailed vascular and neurological evaluation. Preoperative labs routinely include a complete blood count, basic metabolic panel, lipid panel (including HDL, LDL, and Triglycerides), coagulation profile (including PT, PTT, and INR), and hemoglobin A1C. It is also recommended to obtain a baseline EKG for all patients and a chest x-ray (CXR) if the patient is known to have pulmonary disease or is more than 65 years old. During the preoperative evaluation, particular attention should be directed to co-morbid conditions, particularly evidence for ischemic heart disease, congestive heart failure (CHF), insulin-dependent diabetes, or renal failure (creatinine > 2), since these factors can greatly impact the cardiac risk stratification of the patient. All patients with carotid disease should have their regimen of medical therapy optimized and all patients planned to undergo CAS are recommended to have aspirin once a day for at least 1 week, and Plavix 75mg once a day for at least 3 days prior to the procedure. Following CAS, all patients should continue aspirin lifelong and Plavix for at least 6 weeks.

Prior to intervention, a diagnostic aortic arch, cervical carotid, and cerebral angiogram is required. This can be performed immediately prior to the CAS procedure or use a high-resolution magnetic resonance angiogram (MRA) or CT angiogram as a substitute.

Arch angiogram helps to assess anatomy of supra-aortic trunks, anticipate difficult aortic arch (Type III arch, bovine arch), and to facilitate carotid cannulation. Cerebral angiograms with at least two views are to determine patency of intracranial vessels and presence of intracranial diseases (arteriovenous fistula, arteriovenous malformation, or intracranial tumor). Preoperative MR or CT angiogram can help to acquire this critical information prior to the planned CAS procedures. A risk-benefit analysis with this information in hand will help the operator determine if CAS is appropriate, the timing of CAS, or whether the patient is more appropriate for an open surgical repair. One cannot over emphasize that appropriate patient selection and sound judgment is critical when planning a CAS procedure.

On the preoperative imaging, the operator should pay particular attention to the arch anatomy, carotid tortuosity, and the extent of the carotid disease.

An extremely tortuous vessel, a string sign, evidence of free-floating thrombus, and densely calcified lesions are associated with significant complications, particularly distal embolization, during CAS. These anatomical features are contraindications for CAS and should be taken into serious consideration if a CAS is planned. Alternative treatment approach should be evaluated for patients with high-risk anatomical feature for CAS. In addition to routinely usage of embolic protection device (EPD), alternative carotid access strategy, neuro-rescue measures, and various devices should be readily available and be accessed if necessary.

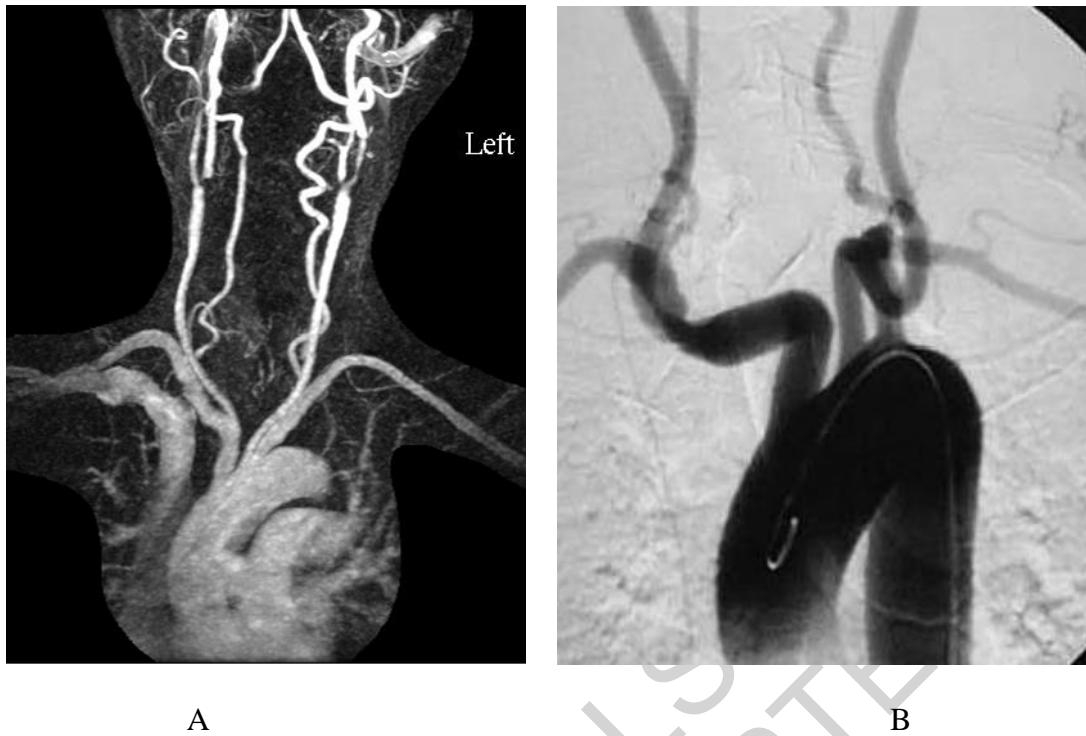


Figure 1. (A) A preoperative MRA of an aortic arch shows aortic arch anatomy and its supra-aortic trunks (B). Digital subtraction arch angiogram showed a tortuous left common carotid artery that poses difficulty during CAS

Listed below are devices/equipment commonly required for a CAS procedure.

1. Imaging
 - a. Endovascular suite with high quality image intensifier or a mobile C-arm unit
 - b. Digital subtraction capabilities
2. Drugs
 - a. Heparin 100mg/kg (or other substitutes are required)
 - b. Atropine 0.5-1mg (may be needed)
 - c. Aspirin (required)
 - d. Plavix (required)
 - e. Vasoactive medication (may be needed)
3. Commonly used Wires
 - a. 0.035" Benston wire, J wire, or other starter wire (needed)
 - b. 0.035", 260 cm, stiff angled glide wire or an alternative stiff wire (needed)
 - c. 0.014" Stabilizer wire (a buddy wire that is occasionally required)
 - d. 0.035" Amplatz superstiff guide wire (occasionally required)
4. Commonly used selective Catheters
 - a. Headhunter (H-1) diagnostic catheter, 120-125cm
 - b. Vertebral diagnostic catheter
 - c. JB1 or JB2 angiographic catheter depending on arch anatomy
 - d. Simmons 2 (Sim 2) diagnostic catheter

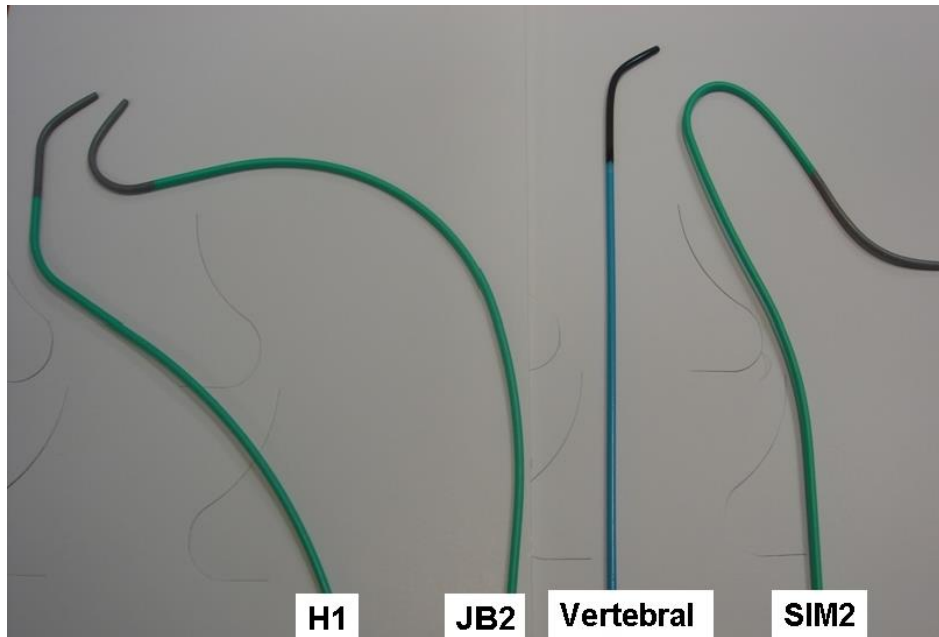


Figure 2. Common used selective diagnostic catheters for common carotid artery cannulation.

5. Sheaths

- a. 5 French introducer sheath
- b. 90cm 6 or 7 French guiding sheath

6. Balloons

- a. 2-3mm coronary balloon (may be needed)
- b. 0.014" 4-6mm monorail angioplasty balloons

7. EPD

- a. 0.014" distal occlusion system (PercuSurge GuardWire balloon)
- b. 0.014" distal filter system (Filterwire EZ, Emboshield, Rx Accunet)
- c. 0.014" proximal occlusion system (Parodi anti-embolization catheter)

8. Stents

- a. Wallstent (Boston Scientific)
- b. Precise (Cordis)
- c. AccuLink (Abbott)
- d. Exact Stent (Abbott)

9. Miscellaneous

- a. Non-ionized contrast agent
- b. Aspiration Catheters (may be needed)
- c. 0.014" micro-puncture kit
- d. Percutaneous closure device

-
-
-

TO ACCESS ALL THE 24 PAGES OF THIS CHAPTER,
Visit: <http://www.eolss.net/Eolss-sampleAllChapter.aspx>

Bibliography

- [1]. Thom T, Haase N, Rosamond W, Howard VJ, Rumsfeld J, Manolio T, Zheng ZJ, Flegal K, O'Donnell C, Kittner S, Lloyd-Jones D, Goff DC Jr, Hong Y, Adams R, Friday G, Furie K, Gorelick P, Kissela B, Marler J, Meigs J, Roger V, Sidney S, Sorlie P, Steinberger J, Wasserthiel-Smoller S, Wilson M, Wolf P; American Heart Association Statistics Committee and Stroke Statistics Subcommittee. (2006) Heart disease and stroke statistics--2006 update: A report from the American heart association statistics committee and stroke statistics subcommittee. *Circulation.*;113:e85-151
- [2]. North American symptomatic carotid endarterectomy trial collaborators (1991) Beneficial effect of carotid endarterectomy in symptomatic patients with high-grade carotid stenosis.. *N Engl J Med.*;325:445-453
- [3]. Goldstein LB, Hasselblad V, Matchar DB, McCrory DC. (1995) Comparison and meta-analysis of randomized trials of endarterectomy for symptomatic carotid artery stenosis. *Neurology*;45:1965-1970.
- [4]. Executive committee for the asymptomatic carotid atherosclerosis study (1995) Endarterectomy for asymptomatic carotid artery stenosis.. *Jama.*;273:1421-1428
- [5]. Hobson RW 2nd, Weiss DG, Fields WS, Goldstone J, Moore WS, Towne JB, Wright CB. (1993) Efficacy of carotid endarterectomy for asymptomatic carotid stenosis. The Veterans Affairs Cooperative Study Group. *N Engl J Med*; 328:221-7.
- [6]. The European carotid surgery trialists collaborative group (1995) Risk of stroke in the distribution of an asymptomatic carotid artery.. *Lancet.*;345:209-212
- [7]. Abbott AL. (2009)Medical (nonsurgical) intervention alone is now best for prevention of stroke associated with asymptomatic severe carotid stenosis: Results of a systematic review and analysis. *Stroke.*;40:e573-583
- [8]. Brott TG, Halperin JL, Abbara S, Bacharach JM, Barr JD, Bush RL, Cates CU, Creager MA, Fowler SB, Friday G, Hertzberg VS, McIff EB, Moore WS, Panagos PD, Riles TS, Rosenwasser RH, Taylor AJ. (2011a) asa/accf/aha/aann/aans/acr/asnr/cns/saip/scai/sir/snis/svm/svs guideline on the management of patients with extracranial carotid and vertebral artery disease: Executive summary. A report of the American College of Cardiology Foundation/American Heart Association task force on practice guidelines, and the American Stroke Association, American Association of Neuroscience Nurses, American Association of Neurological Surgeons, American College of Radiology, American Society of Neuroradiology, Congress of Neurological Surgeons, Society of Atherosclerosis Imaging and Prevention, Society for Cardiovascular Angiography and Interventions, Society of Interventional Radiology, Society of Neurointerventional Surgery, Society for Vascular Medicine, and Society for Vascular Surgery. *Circulation.*;124:489-532
- [9]. Ricotta JJ, Aburahma A, Ascher E, Eskandari M, Faries P, Lal BK (2011) Updated society for vascular surgery guidelines for management of extracranial carotid disease: Executive summary. *J Vasc Surg.*;54:832-836
- [10]. McCabe DJ, Brown MM, Clifton A.(1999) Fatal cerebral reperfusion hemorrhage after carotid stenting. *Stroke.*;30:2483-2486

- [11]. Rapp JH, Pan XM, Sharp FR, Shah DM, Wille GA, Velez PM, Troyer A, Higashida RT, Saloner D.(2000) Atheroemboli to the brain: Size threshold for causing acute neuronal cell death. *J Vasc Surg.*;32:68-76
- [12]. Willfort-Ehringer A, Ahmadi R, Gruber D, Gschwandtner ME, Haumer A, Haumer M, Ehringer H.(2004) Arterial remodeling and hemodynamics in carotid stents: A prospective duplex ultrasound study over 2 years. *J Vasc Surg.*;39:728-734
- [13]. (2001) Endovascular versus surgical treatment in patients with carotid stenosis in the carotid and vertebral artery transluminal angioplasty study (cavatas): A randomised trial. *Lancet.*;357:1729-1737
- [14]. Yadav JS, Wholey MH, Kuntz RE, Fayad P, Katzen BT, Mishkel GJ, Bajwa TK, Whitlow P, Strickman NE, Jaff MR, Popma JJ, Snead DB, Cutlip DE, Firth BG, Ouriel K.(2004) Protected carotid-artery stenting versus endarterectomy in high-risk patients. *N Engl J Med.*;351:1493-1501
- [15]. Gurm HS, Yadav JS, Fayad P, Katzen BT, Mishkel GJ, Bajwa TK, Ansel G, Strickman NE, Wang H, Cohen SA, Massaro JM, Cutlip DE. (2008) Long-term results of carotid stenting versus endarterectomy in high-risk patients. *N Engl J Med.*;358:1572-1579
- [16]. CARESS Steering Committee. (2003) Carotid revascularization using endarterectomy or stenting systems (caress): Phase I clinical trial. *J Endovasc Ther.*;10:1021-1030
- [17]. Mas JL, Chatellier G, Beyssen B; EVA-3S Investigators (2004) Carotid angioplasty and stenting with and without cerebral protection: Clinical alert from the endarterectomy versus angioplasty in patients with symptomatic severe carotid stenosis (eva-3s) trial. *Stroke.*;35:e18-20
- [18]. Ringleb PA, Allenberg J, Bruckmann H, Eckstein HH, Fraedrich G, Hartmann M, Hennerici M, Jansen O, Klein G, Kunze A, Marx P, Niederkorn K, Schmiedt W, Solymosi L, Stingele R, Zeumer H, Hacke W..(2006) 30 day results from the space trial of stent-protected angioplasty versus carotid endarterectomy in symptomatic patients: A randomised non-inferiority trial. *Lancet.*;368:1239-1247
- [19]. Ederle J, Dobson J, Featherstone RL, Bonati LH, van der Worp HB, de Borst GJ, Lo TH, Gaines P, Dorman PJ, Macdonald S, Lyrer PA, Hendriks JM, McCollum C, Nederkoorn PJ, Brown MM. (2010) Carotid artery stenting compared with endarterectomy in patients with symptomatic carotid stenosis (international carotid stenting study): An interim analysis of a randomised controlled trial. *Lancet*, 2010., 375:985-997
- [20]. Bonati LH, Dobson J, Algra A, Branchereau A, Chatellier G, Fraedrich G, Mali WP, Zeumer H, Brown MM, Mas JL, Ringleb PA. (2010) Short-term outcome after stenting versus endarterectomy for symptomatic carotid stenosis: A preplanned meta-analysis of individual patient data. *Lancet.*;376:1062-1073
- [21]. Brott TG, Hobson RW, 2nd, Howard G, Roubin GS, Clark WM, Brooks W, Mackey A, Hill MD, Leimgruber PP, Sheffet AJ, Howard VJ, Moore WS, Voeks JH, Hopkins LN, Cutlip DE, Cohen DJ, Popma JJ, Ferguson RD, Cohen SN, Blackshear JL, Silver FL, Mohr JP, Lal BK, Meschia JF. (2010) Stenting versus endarterectomy for treatment of carotid-artery stenosis. *N Engl J Med.*;363:11-23
- [22]. Zhou W, Dinishak D, Lane B, Hernandez-Boussard T, Bech F, Rosen A. (2009) Long-term radiographic outcomes of microemboli following carotid interventions. *J Vasc Surg.*;50:1314-1319
- [23]. Bonati LH, Jongen LM, Haller S, Flach HZ, Dobson J, Nederkoorn PJ, Macdonald S, Gaines PA, Waaijer A, Stierli P, Jager HR, Lyrer PA, Kappelle LJ, Wetzel SG, van der Lugt A, Mali WP, Brown MM, van der Worp HB, Engelter ST. (2010) New ischaemic brain lesions on mri after stenting or endarterectomy for symptomatic carotid stenosis: A substudy of the international carotid stenting study (icss). *Lancet Neurol.* 9:353-362
- [24]. Tedesco MM, Dalman RL, Zhou W, Coogan SM, Lane B, Lee JT. (2009) Reduction of postprocedure microemboli following retrospective quality assessment and practice improvement measures for carotid angioplasty and stenting. *J Vasc Surg.*;49:607-612; discussion 612-603
- [25]. Tedesco MM, Lee JT, Dalman RL, Lane B, Loh C, Haukoos JS, Rapp JH, Coogan SM. (2007) Postprocedural microembolic events following carotid surgery and carotid angioplasty and stenting. *J Vasc Surg.*;46:244-250

- [26]. Leisch F, Kerschner K, Hofmann R, Steinwender C, Grund M, Bibl D, Leisch FA, Jr., Bergmann H. (2003) Carotid sinus reactions during carotid artery stenting: Predictors, incidence, and influence on clinical outcome. *Catheter Cardiovasc Interv.*;58:516-523
- [27]. Zhou W, Felkai DD, Evans M, McCoy SA, Lin PH, Kougias P, El-Sayed HF, Lumsden AB. (2008a) Ultrasound criteria for severe in-stent restenosis following carotid artery stenting. *J Vasc Surg.*;47:74-80
- [28]. Zhou W, Lin PH, Bush RL, Peden EK, Guerrero MA, Kougias P, Lumsden AB. (2006) Management of in-sent restenosis after carotid artery stenting in high-risk patients. *J Vasc Surg.*;43:305-312
- [29]. Zhou W, Felkai DD, Evans M, McCoy SA, Lin PH, Kougias P, El-Sayed HF, Lumsden AB. (2008b) Ultrasound criteria for severe in-stent restenosis following carotid artery stenting. *J Vasc Surg.*;47:74-80
- [30]. PROGRESS Collaborative Group (2001) Randomised trial of a perindopril-based blood-pressure-lowering regimen among 6,105 individuals with previous stroke or transient ischaemic attack. *Lancet.*;358:1033-1041
- [31]. Amarenco P, Bogousslavsky J, Callahan A, 3rd, Goldstein LB, Hennerici M, Rudolph AE, Sillese H, Simunovic L, Szarek M, Welch KM, Zivin JA. (2006) High-dose atorvastatin after stroke or transient ischemic attack. *N Engl J Med.*;355:549-559
- [32]. Brott TG, Halperin JL, Abbara S, Bacharach JM, Barr JD, Bush RL, Cates CU, Creager MA, Fowler SB, Friday G, Hertzberg VS, McIff EB, Moore WS, Panagos PD, Riles TS, Rosenwasser RH, Taylor AJ. (2011b) asa/accf/aha/aann/aans/acr/asnr/cns/saip/scai/sir/snis/svm/svs guideline on the management of patients with extracranial carotid and vertebral artery disease: Executive summary. A report of the American College of Cardiology Foundation/American Heart Association task force on practice guidelines, and the American Stroke Association, American Association of Neuroscience Nurses, American Association of Neurological Surgeons, American College of Radiology, American Society of Neuroradiology, Congress of Neurological Surgeons, Society of Atherosclerosis Imaging and Prevention, Society for Cardiovascular Angiography and Interventions, Society of Interventional Radiology, Society of Neurointerventional Surgery, Society for Vascular Medicine, and Society for Vascular Surgery. *Circulation.*124:489-532

Biographical Sketch

Wei Zhou, MD, FICA, is currently a Professor of Surgery in the division of Vascular Surgery at Stanford University, Stanford, California. She received her B.S. degree from University of California in San Diego and M.D. degree from New York Medical College. She then underwent general surgery training at University of California-San Diego and vascular surgery fellowship at Baylor College of Medicine. She was appointed as an Assistant Professor of Surgery at Baylor College of Medicine after her fellowship in 2005. In 2007, Dr. Zhou moved to Stanford University as an Associate Professor of Surgery. She is actively involved several committees of Society for Vascular Surgery; chairs the Education Committee of Association for Academic Surgeons, and is the past chair of Industry Relationship Committee of Peripheral Vascular Surgery Society. She is also an active committee member in Society of University Surgeons and Society of Clinical Vascular Surgery. She is a reviewer for 11 scientific journals and authored over 80 publications. Her major research interest is the outcome of carotid disease and vascular biology. Her research work is funded by the National Institute of Health, American Heart Association, and Veteran Administration.